

# Discordance Rate between Thyroid Fine Needle Aspiration Cytology and Histopathologic Diagnosis

Wondwossen Ergete, Daniel Abebe

## Abstract

Fine Needle Aspiration (FNA) of the thyroid is a low cost procedure, which can give an accurate diagnosis promptly. The objective of this study was to assess the diagnostic accuracy of Fine needle Aspiration of the thyroid against histopathologic (gold standard) examinations done during January 1994-December 2000. Three hundred forty-four patient records were included in the study. The study revealed the sensitivity and specificity of FNA to be 67% and 84.7% respectively. The FNA was non diagnostic in 0.87% of cases, suspicious in 2% of cases and were diagnostic in 97% of cases. The False negative and False Positive rates in this study were 4.5% and 13.5% respectively. It was concluded that FNA is useful as the initial diagnostic test in the evaluation of thyroid nodules. [*Ethiop.J.Health Dev.* 2002;16(2):227- 231]

## Introduction

Fine Needle Aspiration (FNA) of the thyroid is a well-established diagnostic procedure used in the management of patients with thyroid nodules aside from surgical excision. FNA has the single best predictive value of any test available currently. It is a relatively cost effective procedure that provides specific diagnosis rapidly. Because of its ease and safety, the procedure has gained patient acceptance. It is often used as the initial screening test for patients with thyroid nodules (1).

Thyroid nodules cause apprehension because their behavior is unpredictable. Their prevalence depends on the population studied, increases linearly with age by an average of 0.08% per year, and is much greater among women. Prevalence ranges from 4% to 10% in the general adult population and from 0.2% to 1.5% in children (2). The majority of clinically detectable thyroid nodules are non-neoplastic, only 5-30% of these are malignant and require surgical intervention (3). The vast majority of the masses are benign nodular goiter, which is a disease affecting 4% to 7% of the population.

The incidence of malignant disease in cold nodules varies from 9% to 35% (average 25%) and the incidence of carcinoma in cystic lesions of less than four centimeter in size is less than 2% (4).

The main purpose of thyroid FNA is to identify nodules that require surgery and those with benign nodules that can be followed up clinically and decrease overall the number of thyroidectomies for patients with benign diseases. This retrospective study was undertaken to determine the correlation between the fine needle aspiration and histopathologic (gold standard) diagnoses of the thyroid swellings in Tikur Anbessa Hospital, Department of Pathology, Faculty of Medicine, Addis Ababa University between January 1994 and December 2000.

## Method

A retrospective review of the biopsy requisition forms and reports at the Department of Pathology, Faculty of Medicine, Addis Ababa University (FMAAU) was performed from January 1994 to December 2000. The records of all female and male patients who had undergone FNA and subsequent histopathologic confirmation at the Department of Pathology, FMAAU were

included. The histopathologic confirmation consisted mainly excisional biopsy. Either a pathology resident or a pathologist procured the fine needle aspirations as follows: a 20-23-gauge needle was attached to a 10ml syringe, which was mounted on aspiration Cameco gun. After the skin was cleaned with cotton swab soaked in ethyl alcohol and dried; one or two separate passes were made into the lesion with the needle. During each pass the needle was moved throughout the lesion multiple times while aspirating. Smears from the aspirates were air dried and stained by the May Grünwald Giemsa stain. The cytologic diagnosis was categorized into four groups: negative for malignancy, indeterminate (suspicious) for malignancy, positive for malignancy and not diagnostic specimen. Negative for malignancy encompassed colloid goiters and inflammatory lesions. The suspicious (indeterminate) category encompassed diagnoses when aspirates didn't fulfill strict criteria for malignancy. The positive for malignancy category encompassed diagnoses of papillary carcinoma, follicular neoplasm, medullary carcinoma, and the less common entity: Hurthle-cell neoplasm. Follicular neoplasms as well as Hurthle cell neoplasm included follicular or Hurthle cell adenoma and follicular or Hurthle cell carcinoma. No attempt was made to distinguish between these two cytologically because it needs histologic evidence of capsular and/or vascular invasion and distant metastases. 'Positive' and 'Negative' for malignancy were classified as 'determinate' results.

The cytologic diagnoses were compared with the gold standard histopathologic diagnoses. FNAs with diagnostic results were categorized as either 'correlating' with histologic diagnoses or discrepant. A false negative diagnosis was defined as a diagnosis of a non-

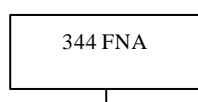
neoplastic entity given to a malignant lesion. A false positive cytologic diagnosis was defined as a malignant neoplasm given to a benign lesion.

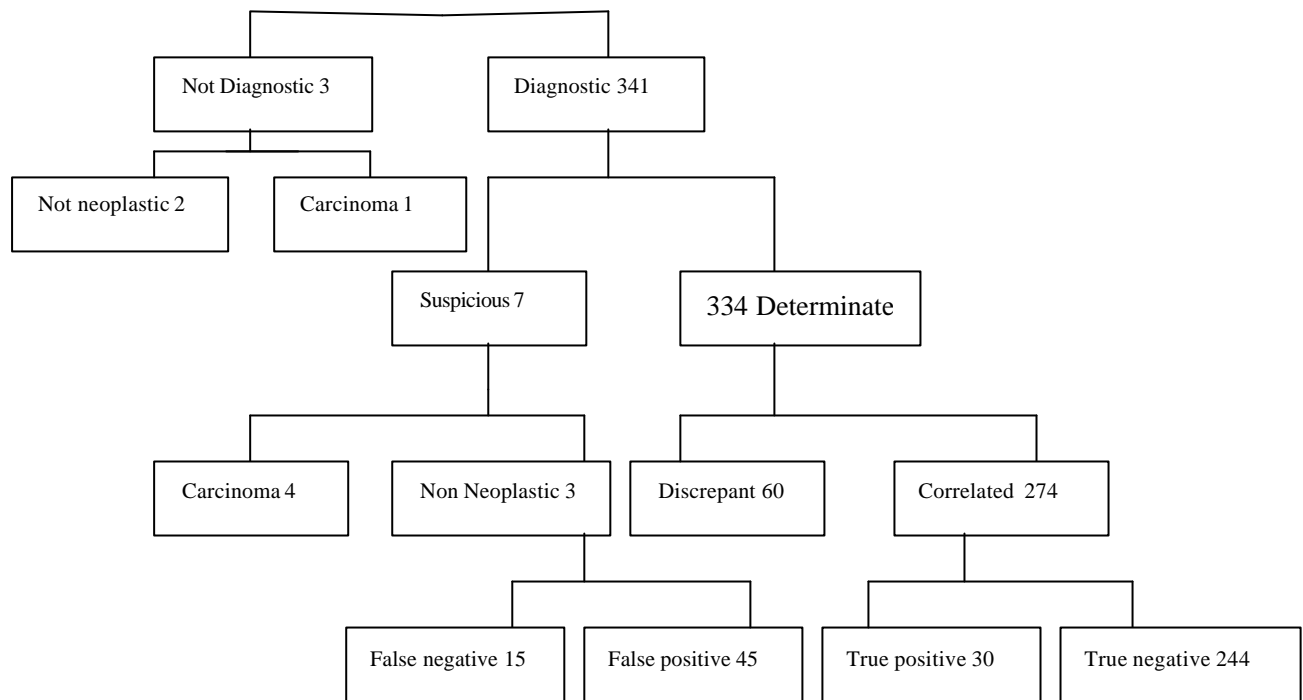
## Results

A total of 344 cases that fulfilled the study criteria were identified. Only 3 (0.87%) FNA smears were unsatisfactory for evaluation. In these three the histopathologic diagnoses were two colloid goiters and one carcinoma. All histopathologic specimens were adequate to make the final histopathologic diagnoses. There were 273 female and 71 male patients. The mean age of males was 39 yrs and females was 34 yrs. Seven cases (2%) were categorized as suspicious (i.e., indeterminate). Four out of seven corresponded histopathologically to carcinoma (two papillary, one each follicular and undifferentiated carcinomas). The rest three were non-neoplastic (two colloid goiter and one subacute thyroiditis). Three hundred thirty four cases (97%) were diagnostic. When compared with the histopathologic (the gold standard) diagnosis, 60 (18%) of the diagnostic cases were discrepant (15 false negative and 45 false positive but 274 cases (82%) were correlated (30 true positive and 244 true negative) (Figure 1). The false negative rate was 4.5% and a false positive rate of 13.5%. The overall sensitivity and specificity for cytologic diagnosis were 67% and 84.7% respectively (Table 2). The accuracy of FNA in this series is 82% (Table 1).

Among the 15 false negative cases, 13 were either cyst with or without nodular goiter on FNA but were diagnosed histopathologically as papillary carcinoma. The remaining two were nodular colloid goiter by FNA and corresponded with follicular carcinoma histologically.

Figure 1: cytohistologic correlation of 344 cases in Department of Pathology, Faculty of Medicine, AAU (Jan 1994 - Dec 2000)





The majority of false positive cases (40 out of 45 cases) were diagnosed cytologically as follicular neoplasm when corresponded histologically; 23 of them were follicular or Hurthle cell adenoma, 15 nodular colloid goiter, two inflammatory lesions (Hashimoto's thyroiditis). The remaining five patients diagnosed as papillary carcinoma cytologically were colloid goiter histologically.

**Table 1: Summary of FNA of 344 thyroid nodules**

Inadequate sample	0.87%
False negative	4.5%
False positive	13.5%
Sensitivity	67%
Specificity	84.7%
Accuracy	82%

**Table 2: Sensitivity and Specificity**

Screening (FNA)	Diagnostic (Histopathology)	
	+	-
+	30	45
-	15	244

## Discussion

The diagnostic sensitivities reported in the literature range widely, from 43% to 99%, and specificity ranges from 47% to 100% (3-5). Factors contributing to this broad range of sensitivity and specificity are the handling of

suspicious cases, the length of follow up, and the inclusion of occult papillary carcinoma in the category of false negative diagnosis. Eva et al. (3) reported overall 93% sensitivity and 96% specificity. In this study the sensitivity and specificity of thyroid FNA were 67% and 84% respectively, which is within the range but much lower than Eva's series. This might be explained by the limited year of experience in the cytology unit. Concerning correlation in our study 82% of cases were correlated which is somewhat comparable with the study of Eva et al. (i.e. 88% of the diagnostic cases).

In the literature the false negative rate ranges from 1-11% including the recent study done by Eva et al. which was 4%, (6,7), and in our series it was 4.5% comparable to several studies. Since only a small percentage (approximately 10%) of patients with benign cytologic findings undergo surgery, it is difficult to state the true frequency of false negative results (4). Furthermore FNA is considered to be a screening procedure. Particular attention should be given to limit false negative diagnosis to a minimum probably at the expense of accepting some false-positive diagnoses. This is suggested by Eva et al as one approach to minimize the missing of true positive cases requiring surgical intervention. The most common cause

of false negative report in our series (13 out of 15 cases) was cytologically diagnosing as a cyst subsequently diagnosed histologically as papillary carcinoma. This is also a commonly encountered diagnostic pitfall in most studies (8). Strict criteria for specimen adequacy could help to reduce markedly the false negative cases as it was noted by Langway et al. (5). The recommended criteria vary slightly among institutions and experts in the field. They have made the following recommendations. Gollener et al (7) recommended 5-6 groups of well-preserved follicular cells, with each group containing 10 or more cells; Kini recommended 8-10 tissue fragment of well preserved follicular epithelium on at least two slides. Nguyen et al considered 10 clusters, each with greater than 20 follicular cells as satisfactory specimen. And recently a task force affiliated with papanicolaou society of cytopathology stated that the presence of follicular epithelium may not be required if abundant colloid or macrophages are present with paucity of follicular cells and repeat aspiration or further investigation is recommended for nodules greater than 4 cms. In this series the large number of false positive results affecting 40 cases were due to over diagnosis of follicular neoplasm. This is predominantly because of overlapping cyto-logical criteria among hyperplastic adeno-matous nodules in goiter, follicular adenoma and well-differentiated follicular carcinoma (9). The latter ideally needs capsular or vascular invasion to differentiate it from follicular adenoma histologically. Similarly, in the study done by Eva et al, the highest number in false positive cases was found to be due to follicular neoplasm.

Concerning the risk of malignancy in suspicious or indeterminate group in our series four were histologically carcinoma cases out of the total of seven suspicious cases. In other studies it is reported as 15-20% of thyroid aspirates (5) and in the study done by Eva et al nine out of forty cases of indeterminate group were malignant. Thus, suspicious (or indeterminate) cases could have a high possibility to be neoplastic and a good chance to be malignant. So, based on this fact it is reasonable to consider patients with indeterminate or suspicious FNA results for

either repeat aspiration or surgical intervention.

Approximately 2% to 15% of the smears are reported to be unsatisfactory for the evaluation (10). This percentage increases greatly when the aspiration is performed by an unskilled physician. In this series the unsatisfactory (not diagnostic) rate was 0.87%. This might suggest that there was an attempt to render cytologic diagnosis in inadequate sample. It cannot be over emphasized that there is a definite urgency to apply strict specimen adequacy criteria for FNA interpretation. In Summary, in this series, the short period of experience in cytologic screening of thyroid malignancy; the sensitivity was 67% and the specificity was 84%. There were 13.5% false positive and 4.5% false-negative results. The results are quite encouraging and FNA is recommended as the initial diagnostic test in the evaluation of thyroid nodules. It is a good screening test and saves many needless thyroidectomies. It is recommended to apply strict specimen adequacy criteria for FNA interpretation which is likely to decrease the rates of false-positive and false-negative FNA diagnoses.

#### **Acknowledgment**

The authors are grateful to W/o Zewdinesh Shentema for her secretarial assistance.

#### **References**

1. Volanda CD. Fine-needle aspiration and diagnosis of thyroid cancer. *Endocrinology and metabolism. Clinics of North America* 1996; 25:69-72.
2. Risgway EC. Clinical evaluation of solitary thyroid nodules. In: Ingbar SH, Braveman LE, eds. *Werner's The Thyroid. A Fundamental and Clinical Text.* Philadelphia, GB: Lippincott, 1986:1377-83.
3. EVA MW, Marrille H, Shailesh UP, et al. Fine-needle aspiration of the thyroid: Rate and causes of cytohistopathologic discordance. *Diagn Cytopathol* 2000;23: 233-37.
4. Ramacciotti CE, Pretorius HT, Chu EW, Barsky SH, Brennan MF, Robbins J. Diagnostic accuracy and use of aspiration biopsy in the management of thyroid

nodules. Arch Intern Med 1984;144:1169-1173.

5. Caraway NP, Sneig En, Samman NA, diagnostic pitfalls in thyroid fine needle aspiration, a review of 394 cases. Diagn Cytopathol 1993;9:345-350.
6. Sidavy MK, Del Vecchio DM, Knoll SM. Fine needle aspiration of thyroid nodules: correlation between cytology and histology and evaluation of discrepant cases. Cancer 1997;81:253-259.
7. Goellner JR, Ghianb H, Grantis J. FNAC of the thyroid. Acta Cytol 1987;1:587-90.
8. Svante R. Ovell. Manual and atlas of fine needle aspiration. Churchill Livingstone, second edition. 1995:96-97.
9. Ravinsky E, Safneck JR. Fine-needle aspirates of follicular lesions of the thyroid gland: the intermediate type smear. Acta Cytol 1990;34:813-820.
10. Boey J, Hsu C, Collins RJ: False-negative errors in fine needle aspiration biopsy of dominant thyroid nodules. A prospective follow up study. World J Surg 1986; 10:623-30.



